Use of Temporalis myofascial flap for reconstruction of maxillectomy defect

Rahman MM[1], Mamood MA[2], Rubel ATMT[3], Tymur FR[4], Talukder MA[5], Haider IA[6]

Abstract:

Reconstruction of maxillectomy defects after tumor resection or trauma ranges from simple obturator, skin graft to pedicled flaps and to free tissue transfer. Several soft tissue flaps can be used for reconstruction of maxillectomy defect. Keeping the parameters of reconstruction in mind it is ideal to reconstruct the maxillectomy defect with either the free flaps or the regional flaps. Of all regional flaps, the temporalis myofascial flap (TMF) provides a high degree of reliability, vascularity, adequate bulk, and proximity to the defect in the oral and maxillofacial region.

Post maxillectomy defects in 12 patients were reconstructed using temporalis myofascial flap in Dhaka Dental College Hospital between March 2013 and December 2014 of which 08 were male and 04 female. Malignant disease involved maxilla in 11 cases (squamous cell carcinoma in 09 cases, adenoid cystic carcinoma in 01 case, osteosarcoma in 01 case) while 01 patient had benign tumour (Ameloblastoma) of maxilla.

Acceptable functional and aesthetic outcome were observed in all the cases. Temporalis myofascial flap was considered a good choice for reconstruction of most of the intraoral defects especially those in palatal and buccal region.

(Bangladesh Dental Journal 2016; 32: 4-8)

Introduction:

The maxillary defect after ablative tumor surgery always involves the mucosal lining, the midface skeletal structures and the adjacent soft tissue.[1] Reconstruction of such a defect remains challenge because of the 3-dimensional structure of the midface. The final goals for maxillectomy defect reconstruction are to give support to the orbital content and minimizing changes in globe position, orbital volume, to maintain a patent nasal airway and oronasal separation, speech quality, and potential dental rehabilitation and to restore an adequate and symmetric facial contour with the other side of the face.

Individuals diagnosed as having cancer of the head and neck is overwhelmed by the notion of potential functional sequelae owing to treatment involving surgery, radiation therapy, and chemotherapy. Limited ability to speak and eat often lead to social isolation, loss of employment, and decreased quality of life.[2] All of this may cumulate to patients' inability to care for themselves and their families. Loss of employment causes the financial burden on society when patients come to rely on social welfare systems. Compromised communicative functions resulting in a distressing impact on quality of life.[3]

In the past, a prosthetic obturation was the only reconstruction option but it has limitation like instability, poor retention, and oronasal incompetence. The resection of oral cavity tumor and malignancies often causes functional disabilities like deglutition and articulation, poor speech, nasal regurgitation of food, and also aesthetic outcomes.[4] Thus surgical procedures performed on the region of head and neck require synchronous tissue reconstruction in order to close the defect of the removed tumor. Palato-maxillary defects are inherently challenging because they generally involve more than one mid-facial structure, are composite in nature and the complex three-dimensionality of the region must be accounted for. Various methods of palato-maxillary reconstruction include regional flaps, and free grafts both simple and complex are advised. The choice of reconstruction method should be based on

1. Dr. Md. Masudur Rahman, BDS, MS (OMS), Assistant Professor, Department of Oral and Maxillofacial Surgery, Dhaka Dental College Hospital.
2. Dr. Md. Apel Mamood, BDS, FCPS (OMS), Registrar, Department of Oral and Maxillofacial Surgery, Dhaka Dental College Hospital.
3. Dr. ATM Tarifuzzaman Rubel, BDS, FCPS(OMS), Assistant Professor, Department of Oral and Maxillofacial Surgery Dhaka Dental College Hospital.
4. Dr. Fazla Rubby Tymur, BDS, Assistant Registrar, (OMS), Department of Oral and Maxillofacial Surgery, Dhaka Dental College Hospital.
5. Dr. Morshed Alam Talukder, BDS, FNST, MS (OMS), Associate Professor, Department of Oral and Maxillofacial Surgery, Dhaka Dental College Hospital.
6. Prof. Dr. Ismat Ara Haider, BDS, DDS, MS (OMS), Professor & Head, Department of Oral and Maxillofacial Surgery, Dhaka Dental College Hospital.

Address of Correspondence: Dr. Md. Masudur Rahman, BDS, MS(OMS), Assistant Professor, Department of Oral and Maxillofacial Surgery, Dhaka Dental College Hospital.

reliability, length of surgical procedure, burden on the patient, and an acceptable functional and aesthetic outcome. Free flaps and regional flaps are best for reconstruction of larger defects. Free flaps have the advantages of availability of bulk, minimal donor site morbidity and vascularity. However, these flaps need a high degree of surgical and technical expertise and considerable operative time. Considering these factors loco regional flaps for such reconstructions are always a preferred option. Of all regional flaps the temporalis muscle provides a high degree of reliability, vascularity, adequate bulk, and proximity to the defect in the oral and maxillofacial region.[2, 3, 4]

We present our own experience in using the temporalis myofascial flap (TMF) for the reconstruction of palato-maxillary tissue following the extensive ablation of the maxilla without major complications.

Materials and methods:

This Descriptive study was carried out at the department of Oral and Maxillofacial Surgery Dhaka dental college hospital. This study was completed from March 2013 to December 2014. Total 12 patients were included in this study age ranging from 31 to 65 with average age of 52 years. Patients with large defect after oncologic resection of maxilla were included in this study. Patient who had undergone radiation therapy, previous surgery or trauma to the temporal region were not included in this study. Medically compromised patients, who could not tolerate general anesthesia, excluded from the study.

The temporalis muscle was exposed by using a coronal incision with a preauricular extension. Dissection carried out at a subgaleal plane to expose the muscle. Then, it was mobilized subperiosteally from its deep origin in the temporal fossa. Anteriorly, the muscle was elevated from the lateral aspect of the orbit and inferiorly down to the temporal crest. Particular care was taken to preserve the blood vessels entering from its inferior aspect. The zygomatic arch exposed to rotate the muscle beneath the arch into the oral cavity. In two cases segment of arch were resected to facilitate the rotation. in three cases coronoidectomy were done to increase the arc of rotation. The muscle pulled through the tunnel and sutured intraorally. A drain placed at the subgaleal plane, the coronal flap repositioned, and the incision closed in layers. Vitality of flap was assessed by color of flap (normal, pale or bluish), Suture dehiscence, and marginal necrosis, presence of infection or pus discharge. Finally, degree of satisfaction in mastication, mouth opening, and speech, facial nerve function and flap esthetics was documented. The collected data analyzed by SPSS statistical package version 11.0.

Result:

We investigated a total 12 patients with maxillectomy defect. Among them 8 were male and 4 female. Age ranges from 31 to 65 with average 52 years.

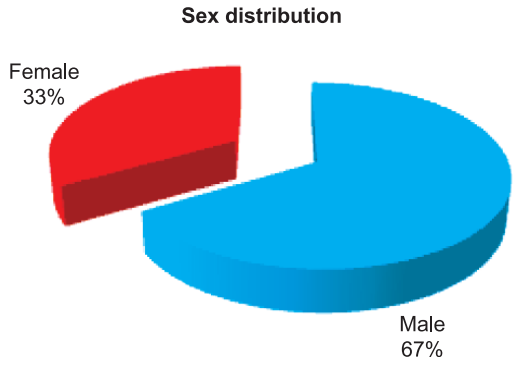

Fig.-1: *Sex distribution of the study.*

Eleven patients had malignant disease of maxilla (09 were squamous cell carcinoma, 01 adenoid cystic carcinoma and 01 osteosarcoma) while other one had benign tumour (Ameloblastoma).

Table-I

Diagnosis of disease

Name of the disease	Number of cases
Oral squamous cell carcinoma	09
Adenoid cystic carcinoma	01
Osteosarcoma	01
Ameloblastoma	01

Flap taking was uneventful in all patients. But minor complications like partial wound dehiscence was observed in 2 cases, marginal flap necrosis in 1 and wound infection in 1 case. They were managed by local wound care and secondary wound closure. The single case of wound infection was managed by regular dressing and proper antibiotic administration based on cultural sensitivity test.

Table-II

Complications

Complications	Case
Full flap necrosis	none
Marginal flap necrosis	01
Partial wound dehiscence	02
Wound infection	01

In 11 patients mouth opening remained normal; one patient developed limited mouth opening later becomes normal after exercise. Quality of speech found satisfactory in all the cases. Difficulty of mastication was observed in 2 cases while 10 other normal masticatory function. Acceptable facial aesthetic found in 10 patients and 2 other had mild facial asymmetry (depression of ipsilateral cheek). None developed oronasal communication.

Table-III

Outcome

Outcome	Case
Adquate mouth opening	12
Good speech	12
Oronasal communication	none
Acceptable facial aesthetic	10
Good masticatory function	10

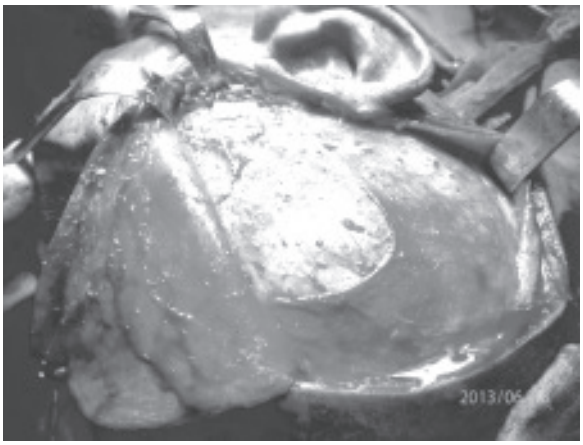

Fig.-1: *Exposing of the flap*

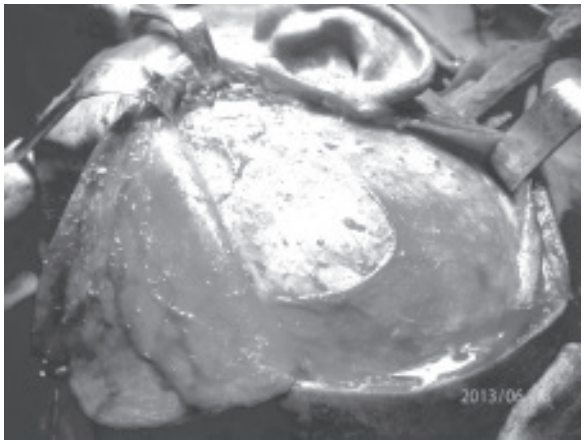

Fig.-2: *Elevation of the flap*

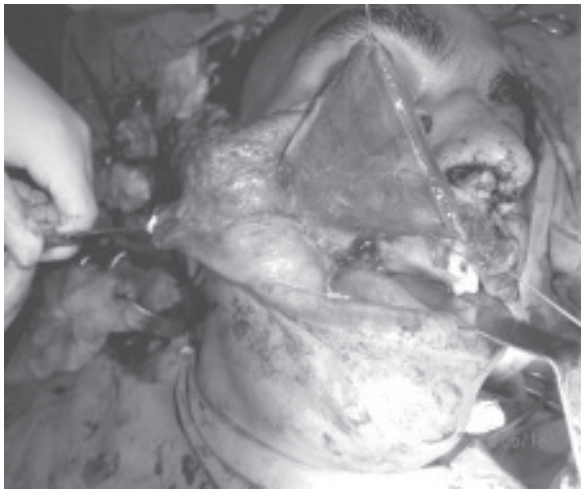

Fig.-3: *Insertion of flap inside the oral cavity.*

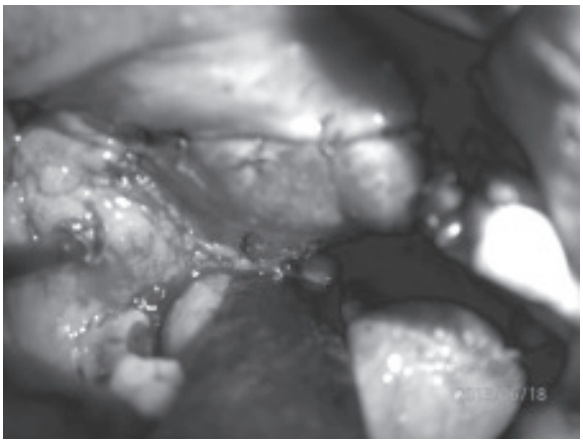

Fig.-4: *Suturing of the flap inside the oral cavity*

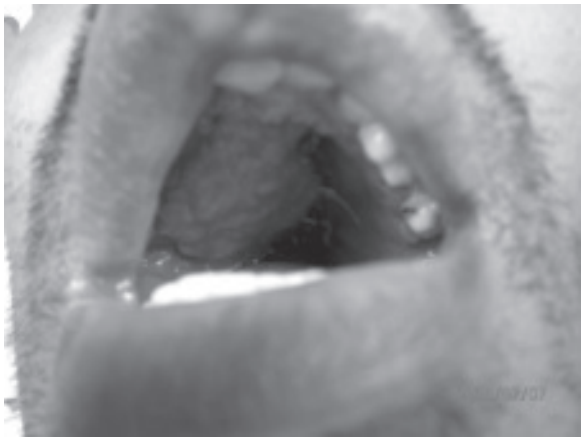

Fig.-5: *Sixth postoperative day.*

Discussion

Post maxillectomy defects are associated with cosmetic deformity and functional disability. Purpose of reconstruction of such a defect is to obturate the nasal

and orbital cavities, separating them from the oral cavity and maintain the facial contour.[5] Causes of post maxillectomy defects include ablative surgery of maxillary cancer or aggressive benign tumour of maxilla.[1,2] Classification systems for midfacial defects were based on the extent of maxillectomy, the size of palatal defect and integrity of the orbital support.[5] Midfacial defects can be simply divided into soft-tissue and bone defects.

Various options for reconstruction of maxillectomy defects are available. Each technique has its advantages and limitations. Traditional reconstruction includes skin grafting and placement of a simple prosthesis for maxillary defect. Common regional flaps for reconstructing midfacial defects are cervicofacial rotation flap,[6] forehead flap,[7] facial artery musculomucosal flap[8], and temporalis muscle flap.[9] A variety of free tissue transfers have been advocated and favored by most of the surgeons to repair midfacial defects. The most popular are free scapular fasciocutaneous flap,[10] free fibular osteocutaneous flap,[11] and radial forearm flap.[1] Free flaps are reliable and flexible. The main drawbacks of free tissue transfer are the long operative time, expensive cost, and the additional morbidity in another operative site.[3]

Among all the loco regional flap temporalis myofascial flap is a preferred option due to its proximity, reliability, pliability and ease of harvesting. Although Temporalis myofascial flap has been criticized because of its short arc of rotation modifications of the surgical procedures can be made in order to increase the arc of rotation of the flap. These include resection of the coronoid process and division of the zygomatic arch.[6]

Temporalis myofascial flap was first used by Golovine more than 100 (In the year of 1898) years ago, and it remains a very reliable regional flap for the reconstruction of the maxillofacial defects. The proximity of the oral cavity, palate and the middle third of the face in addition to the reliable vascular pedicle makes the temporalis myofascial flap valuable for reconstruction.[1]

In 2002, Abubakar and colleagues did a study in Virginia, USA on the Temporalis muscle flap in reconstruction of intraoral defects4. The criteria used to evaluate the results of this technique included flap necrosis, facial nerve deficit, limitation of mouth opening and cosmetic deformity from scarring of incision or loss of muscle volume in temporal fossa.[12]

In 2004, Wong TY don study in Taiwan on Temporalis muscle flap for intraoral reconstruction and found that Temporalis muscle flap is simple and safe to apply, it can extend further in the posterior oral cavity and has fewer complications.

In 2005, Estelle's Ferriol JE et al did a study in Spain on Temporalis muscle flap and found that the Temporalis myofascial flap is an excellent choice for maxillofacial region defects reconstruction and no total necrosis of even a single case out of 22 was noted.[13]

In our study among 12 patients all had flap survival (100%).similar observation was found the study of Abubakar in 2002 4. His sample consisted of eight patients reported 100% success rate. in another study ahmed s et al showed 90% success rate and 10% failure due to diabetes and old age.* warrich

We observed marginal necrosis of 1 flap (8.3%) out of 12 patients. Ahmed s et al showed 6.66% of marginal necrosis in a series of 30 cases. On outcome analysis we found good quality of speech, mastication and mouth opening in almost all the cases. None developed oronasal communication. Nearly similar result found in study of abubakar in 2002 probably due to reduced number of sample in both the study.

Thus temporalis myofascial flap was found to be a suitable, reliable and easy reconstructive tool for post maxillectomy defect.

Conclusion:

Based on our study and review of other studies it can be said that temporalis myofascial flap is a good option for reconstruction of post maxillectomy defect due its reliability, survival and aesthetic consideration. In comparison to free flap less operative time made temporalis myofascial flap as a preferred option for midfacial reconstruction. Moreover with zygomatic osteotomy and coronoidectomy this flap can be mobilized for longer distance.

Reference:

1. Mani V, Panda AK. Versatility of temporalis myofascial flap in maxillofacial reconstruction—analysis of 30 cases. Int J Oral MaxillofacSurg 2003; 32: 368-72.
2. Birt BD, Antonyshyn O, Gruss JS. The temporalis muscleflap for head and neck reconstruction. J Otolaryngol. 1987; 16: 179-84.
3. Foster R.D., Anthony J.P., Singer M.I., et al.: Reconstructionof complex midfacial defects. Plast.Reconstr. Surg.,99: 1555-1565, 1997.
4. Wells M.D. and Luce E.A.: Reconstruction of midfacialdefects after surgical resection of malignancies. Clin. Plast. Surg., 22: 79-89, 1995.

5. Wells M.D. and Luce E.A.: Reconstruction of midfacialdefects after surgical resection of malignancies. Clin. Plast. Surg., 22: 79-89, 1995.

6. Juri J. and Juri C.: Advancement and rotation of a largecervicofacial flap for cheek repairs. Plast.Reconstr.Surg., 64: 692-696, 1979.

7. McGregor I.A. and Reid W.H.: The use of the temporalisflap in the primary repair of full-thickness defects of the cheek. Plast.Reconstr. Surg., 45: 326-329, 1970.

8. Pribaz J., Stephens W., Crespo L., et al.: A new intraoralflap: Facial artery musculomucosal (FAMM) flap. Plast. Reconstr. Surg., 90: 421-429, 1992.

9. Antonyshyn O., Gruss J.S. and Birt B.D.: Versatility oftemporal muscle and fascia flaps. Brit. J. Plast. Surg., 41: 118-131, 1988.

10. Swartz W.M., Banis J.C., Newton E.D., et al.: The osteocutaneousscapular flap for mandibular and maxillary reconstruction. Plast.Reconstr. Surg., 77: 530-545, 1986.

11. Sadove R.C. and Powell L.A.: Simultaneous maxillaryand mandibular reconstruction with one free osteocutaneous flap. Plast.Reconstr. Surg., 92: 141-146, 1993.

12. Abubaker O and Abouzgia MB. The temporalis muscleflap in reconstruction of intraoral defects: An appraisalof the technique. Oral Surg, Oral Med, Oral Pathol,OralRadiol and Endodon 2002; 9.

13. EstellesFerriol JE, Carrasco Llatas M, Ferrer RamirezMJ, et al. Temporalis myofascial flap: technique descriptionand results in our patients. ActaOtorrinolaringol Esp 2005; 56: 257-60.